



OPEN ACCESS

Tendons – time to revisit inflammation

Jonathan D Rees,¹ Matthew Stride,² Alex Scott³

► Additional material is published online only. To view please visit the journal online (<http://dx.doi.org/10.1136/bjsports-2012-091957>).

¹Department of Rheumatology, Cambridge University Hospitals NHS Foundation Trust, Cambridge, UK

²Isokinetic Medical Group, FIFA Medical Centre of Excellence, London, UK

³Department of Physical Therapy, University of British Columbia, Vancouver, Canada

Correspondence to

Dr Jonathan D Rees,
Department of Rheumatology,
Cambridge University Hospitals
NHS Foundation Trust,
Hills Road, Cambridge,
CB2 0QQ, UK;
j.rees@doctors.org.uk

Accepted 13 February 2013

ABSTRACT

It is currently widely accepted among clinicians that chronic tendinopathy is caused by a degenerative process devoid of inflammation. Current treatment strategies are focused on physical treatments, peritendinous or intratendinous injections of blood or blood products and interruption of painful stimuli. Results have been at best, moderately good and at worst a failure. The evidence for non-inflammatory degenerative processes alone as the cause of tendinopathy is surprisingly weak. There is convincing evidence that the inflammatory response is a key component of chronic tendinopathy. Newer anti-inflammatory modalities may provide alternative potential opportunities in treating chronic tendinopathies and should be explored further.

INTRODUCTION: THE TENDINOSIS PARADIGM**Pre1990s: the ‘tendinitis’ model**

Prior to the 1990s pain arising from tendons was referred to as tendinitis, implying that inflammation was responsible for the pathological process. This view was both widely accepted and deeply ingrained in the medical literature.¹ Treatment strategies at this time were largely anti-inflammatory in nature and relied heavily on non-steroidal anti-inflammatory drugs (NSAIDs) and corticosteroids.^{2,3}

The move away from ‘tendinitis’: decade of the 1990s

Initially recognised by Puddu *et al*⁴ as long ago as the 1970s, in chronic tendinopathy there is an absence of acute inflammatory cells in the load-bearing regions of tendons.⁴ As histological data became more readily available this view became increasingly recognised. Several studies demonstrated collagen separation, thinning and disruption without an inflammatory cell infiltrate.^{5–7} There was also evidence from some animal studies that degenerative non-inflammatory tendon changes could be experimentally introduced over a brief (1 or 2 week) period.⁸ The pathology of chronic tendon disorders was correctly recognised as being very different from that of a characteristically inflammatory disease, such as rheumatoid arthritis (RA).

The move away from ‘tendinitis’ thinking was summed up concisely in a *BMJ* Editorial by Khan *et al*¹ when practitioners and educators were urged “to accept the irrefutable evidence that the term tendinitis must be abandoned to highlight a new perspective on tendon disorders”. At the time of the Editorial it was necessary for a strong message to be sent that chronic tendinopathy had a different aetiology to inflammatory conditions such as RA, and to emphasise that traditional strategies such as corticosteroid injection and NSAIDs do not adequately address the pathology. Although this remains an important message, we believe to regard

all chronic tendinopathy as entirely non-inflammatory is an oversimplification to the point of being misleading.

Degeneration without inflammation: the paradigm of the 2000s

During the first decade of the 21st century ‘non-inflammatory’ or ‘degenerative’ theories have dominated thinking in tendinopathy. Various models have been proposed. First there are models that attempt to explain why tendons fail. The cumulative damage and vascular insufficiency models fall into the first group.² Second, a group of models attempts to explain why tendons fail to repair themselves and includes the ‘failed healing response’⁹ and the continuum theories of tendinopathy.¹⁰ These theories and the degenerative ‘paradigm’ in general, have become extremely influential.

These ‘degenerative’ models have led to attempts to improve treatment and rehabilitation of the failing tendon. The common treatments that have been adopted during the 1990s can be broadly classified in four groups:

1. Physical exercises including eccentric exercises (EE) or other progressive loading regimes.
2. Treatments using blood and blood products that aim to improve tendon healing and remodelling.
3. Treatments that aim to reduce the pain associated with tendinopathy rather than heal the tendon itself (such as sclerosant or high-volume injections).
4. Extracorporeal shock wave therapy (ESWT).

While there may be a degree of overlap between the treatment groups (eg, ESWT may influence pain processing) the point is none of these treatments are anti-inflammatory in nature.

Certainly much emphasis over the last 10 years has been placed on physical therapies. Eccentric exercises are shown to be effective in managing mid-portion Achilles tendinopathy.¹¹ However, in subsequent studies the very high success rate found in this paper have not been repeated, highlighting the difficulties of EE in less-athletic populations.¹² Furthermore, the success of this technique has not been satisfactorily demonstrated for other tendons.^{13–15} Other rehabilitation models that incorporate a variety of exercises, gradually increasing both load and velocity as the patient’s tolerance improves, have also been explored.^{16,17}

A second area of treatment options are blood and blood products, including bone marrow-derived cells. Initial encouraging data from the equine field demonstrated the potential of stem cells to repair the hypoechoic lesions seen on ultrasound (US).¹⁸ This method, requiring a bone marrow biopsy and in vitro cell expansion, is complicated and has not become routine in human clinical practice.

To cite: Rees JD, Stride M, Scott A. *Br J Sports Med* Published Online First: [please include Day Month Year] doi:10.1136/bjsports-2012-091957

However, in humans, many attempts have been made to help 'repair' tendons by the use of more readily available agents particularly autologous blood and autologous blood products (principally platelet-rich plasma, PRP). The suggestion is that the cells and growth factors (such as vascular endothelial growth factor (VEGF) and insulin-like growth factor-1 (IGF-1) in PRP)¹⁹ or other components of these preparations promote healing. While small uncontrolled studies have shown benefits from these treatments,^{20 21} evidence of the efficacy of these treatment strategies in good-quality *in vivo* studies is currently lacking. Indeed for PRP the level 1 evidence is that PRP is ineffective for mid-portion Achilles tendinopathy.²² Proponents of PRP argue that as there are numerous ways of preparing PRP and some methods may be more effective than others. Nevertheless, there is currently minimal scientific evidence that either PRP or autologous blood is effective when compared to placebo or no injection and further studies are going on.

The limitations of physical therapies and blood product injections in healing tendons have led to a different approach—with the aim of controlling pain through the disruption of the neural ingrowth that often accompanies neovessel formation in chronic tendinopathy.²³ We describe these techniques as denervation procedures. Techniques in this emerging area include sclerosant therapy (eg, polidocanol and possibly dextrose),²⁴ high-volume/tendon stripping injections²⁵ and some surgical techniques (such as paratenon stripping). These techniques are likely to exert their beneficial effect by interruption of neural ingrowth. As shock waves are toxic to peripheral nerves it is possible that ESWT may derive a beneficial effect, at least in part, from a direct effect on peripheral nerves.²⁶

Throughout the last decade the belief that chronic tendon conditions occur due to degeneration has become the prevailing paradigm. Unfortunately, with the possible exception of mid-Achilles tendinopathy, the last decade has not provided us with therapies that are successful at 'healing' the failing tendon.

However, is it certain that inflammation is not involved in the development or progression of tendinopathy? And if so are there other potential treatment options that have been overlooked?

CASE FOR INFLAMMATION IN CHRONIC TENDINOPATHY

Tendinosis myth

Although it was certainly progress to stop referring to all symptomatic tendons as 'tendinitis'; does referring to all chronic tendons as 'degenerative' risks throwing the baby out with the bathwater? Ironically, it is now the 'tendinosis' paradigm that has itself become just as deeply ingrained in the medical literature as the original tendinitis concept. This has had two detrimental consequences. First, it oversimplifies our understanding of the pathological processes. Second it may lead us to ignore potentially effective treatments in chronic tendinopathy.

It is not suggested that acute inflammation is the dominant pathology in all phases of established tendinopathy. However, it is likely that elements of the inflammatory response play a role in the progression or continuation of tendon disrepair. If so, could anti-inflammatory strategies be therapeutic in the chronically pathological tendon? Let us examine the case for the involvement of inflammation and inflammatory mediators in chronic tendinopathy.

'Absence' of inflammatory cells

The 'tendinopathy paradigm' was developed from several historical studies that had failed to show the presence of acute inflammatory cells (such as neutrophils and macrophages) in chronic tendinopathy, or indeed in the early stages of tendon overload.

From this there was an inference that both acute and chronic tendinopathies are devoid of inflammation.

However, there have been major advances in immunohistochemistry and gene expression analysis subsequently. Several studies, in both humans and in animal models, have shown an inflammatory reaction both in established tendinopathy and in the early overload response. Schubert and coworkers²⁷ have demonstrated the presence of macrophages and T and B lymphocytes in chronic Achilles tendinopathy using primary monoclonal antibodies (against CD68 for macrophages, CD3 for detection of T-lymphocytes and against CD20 for detection of B lymphocytes). The authors also studied asymptomatic spontaneously ruptured tendons and in contrast found large numbers of granulocytes (to be expected in the case of an acute traumatic event) but did not see significant numbers of macrophages, T- or B-lymphocytes.

Other studies in chronic tendinopathy have demonstrated increased levels of macrophage-derived interleukin-1 (IL-1),²⁸ cyclo-oxygenase (COX)-1,²⁹ COX-2,^{30 31} IL-6,³² iso-forms of transforming growth factor- β (TGF- β)³³ and increased substance P.³⁴ The classic Achilles overuse model (the Backman model) shows extensive inflammatory changes in the paratenon, with concomitant structural degeneration in the load-bearing tendon, after 3 weeks of acute overload.³⁵

Most studies of tendon pathology have histologically demonstrated an increase in tenocytes and that the tenocytes are larger than normal.³⁶ Tenocytes are well known to proliferate and become more metabolically active in response to cytokines and growth factors that are part of the inflammatory response (eg, platelet-derived growth factor (PDGF), IGF-1 and TGF- β). Thus tenocyte hyperplasia and hypertrophy may provide indirect evidence of up-regulated inflammatory mediators.

It is possible that over time our understanding of tendinopathy will more closely resemble our current understanding of the pathological processes in osteoarthritis (OA). It is no longer believed that OA is caused simply by ageing and cartilage loading but indeed is an active process with infiltration of inflammatory cells (including CD4 T-cells)^{37 38} and natural killer cells.³⁹ Again in OA mechanical overload (of the cartilage tissue) remains a key driver of pathology but the point is the evidence suggests it is mediated through elements of the inflammatory response.

Furthermore, even if inflammation is not seen at a particular point in time, this in itself does not necessarily imply it is not inflammation that has caused tendinopathic changes in the first place. For example, in RA it is not disputed that inflammation causes damage. However, in treated RA (in clinical remission) damage (degeneration) is the key histological finding which will be accompanied by a lack of an inflammatory infiltrate.

Neovessels

One of the most common findings on US of a chronically symptomatic tendon is power Doppler blood flow generally not seen in healthy tendons. This blood flow is referred to as neovascularisation.⁴⁰ It is difficult to know if this neovascularisation represents genuine neoangiogenesis, however in histological studies of chronic tendinopathy angiogenesis is a common finding. There is a body of evidence to suggest that neural 'sprouting' or neoinnervation accompanies neovessel formation, and that the neoinnervation may be a contributor or even responsible for the pain in chronic tendinopathy.²³

Two major molecular mechanisms of angiogenesis have been described—a hypoxia-dependent pathway and also a hypoxia-independent pathway.⁴¹ Pathological tendons are only one of

several pathologies that exhibit neovessel formation. These include inflammatory arthritis (such as RA, psoriatic arthritis and ankylosing spondylitis), OA, ischaemia, malignancy and diabetic retinopathy.

In inflammatory arthritis the neovascularity seen on US is generally regarded as confirming evidence of active inflammation.⁴⁰ VEGF, produced in large quantities by macrophages, is thought responsible for the formation of both neovascularity and neoinnervation.⁴²

Nevertheless, there is a common view that neovessels are synonymous with 'tendinosis'. Certainly many radiologists report neovessels as providing evidence of tendinosis. This is factually incorrect. Tendinosis is a histological term, which confirms that no inflammation is present; its presence cannot be confirmed or rejected following a US scan. It is also misleading as in order for neovessels to sprout it is very likely (in fact probably essential) that inflammatory mediators are involved at some stage in the process.

Power Doppler US assessment of, for example, an enthesal lesion or tendon body in a confirmed rheumatological inflammatory arthritis can look indistinguishable from that seen in a 'degenerative' tendinopathy (see figure 1).

Although the key drivers of neovessel formation in chronic tendinopathy remain the subject of ongoing research, there is strong evidence that the process of neovascularisation involves elements of the inflammatory response. For instance, when substance P is injected peritendinously, the vascularity of the tendon increases.⁴³

Biochemical influences on tendinopathy

There are several biochemical mediators that have been demonstrated to have an influence on the development and progression of chronic tendinopathy. These include the COX-1 and COX-2, matrix metalloproteinases (MMPs) and substance P.

The cyclooxygenase pathway is involved in classical inflammatory conditions (such as RA) and additionally processes with a

more moderate degree of ongoing inflammation (such as osteoarthritis). It is known that peritendinous administration of prostaglandin E1 (PGE1)²⁹ and elevated levels of PGE2^{30 31} may lead to tendinopathic changes in tendon models.

Alterations in the concentrations and activity levels (both increased and decreased) of MMPs are well documented.^{44 45} A prolonged increase in the activity of MMP-1, MMP-3 and MMP-13 could lead to a loss of the biomechanical tendon properties; these MMPs have been linked to the degenerative changes seen in chronic tendinopathy.⁴⁶ MMP-3 was found to be upregulated in the pathological rotator cuff, and correlated with the presence of retear—this MMP is positively regulated both by mechanical load and by substance P.⁴⁷

This process may, at least in part, be secondary to a failure of specific MMP regulation in response to repeated mechanical stimulus. Manipulation of MMPs, possibly through cytokine manipulation or inhibition, therefore provides potential to positively influence the role of MMPs in tendon degeneration and repair.

Substance P has been implicated as a proinflammatory mediator.⁴⁸ Along with calcitonin gene-related peptide (CGRP) these nociceptive agents are significantly expressed in chronic tendinopathy. Substance P not only exerts a proliferative effect on tenocytes—it also increases their ratio of type III : type I collagen mRNA, which could contribute to the formation of smaller collagen fibres seen in tendinopathic tendons.⁴⁷ Substance P also leads tenocytes to adopt a myofibroblast-like phenotype (ie, increased smooth muscle actin expression and increased contractile activity). Thus, the more proliferative and active phenotype of tenocytes observed in chronically painful tendon could result from local production of inflammatory mediators including substance P and potentially others.⁴⁷

So what can we conclude? There is a substantial, and growing, body of evidence indicating that ongoing tendon degeneration is an active process with involvement of many aspects of inflammation-mediated responses.

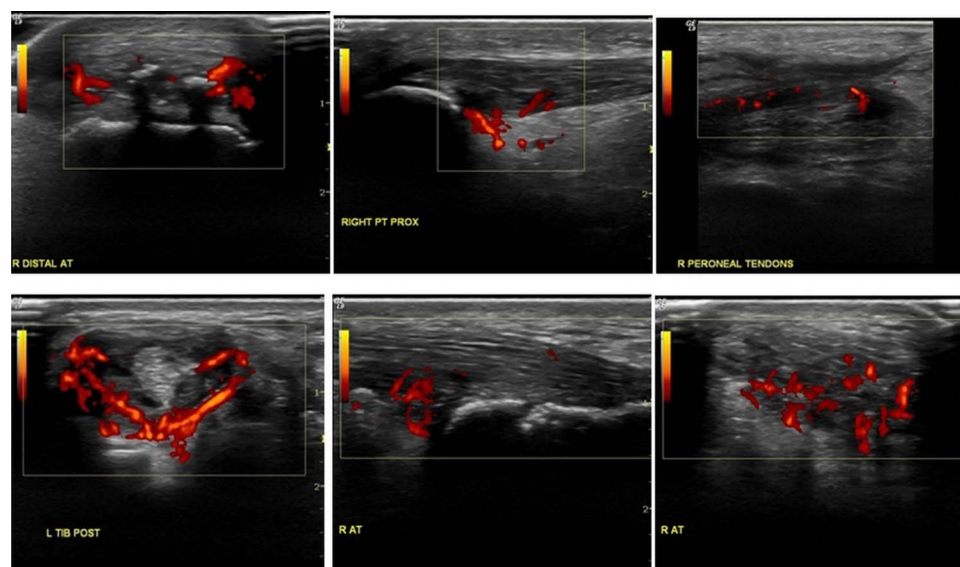


Figure 1 Power Doppler ultrasound in 'overuse' and 'inflammatory' tendon disorders. Sonographically it is often impossible to determine the cause of tendinopathy from Power Doppler signals. The top row of images are all of patients without underlying rheumatological diagnosis and in whom mechanical overload or injury was the cause of the tendinopathy (from left to right insertional Achilles tendinopathy, proximal patellar tendon pathology and mid-peroneal tendon pathology). The bottom row of images is of patients with a known inflammatory rheumatological diagnosis. From left to right tibialis posterior tendinopathy (in RA) and insertional Achilles tendinopathy in a patient with reactive arthritis (longitudinal and transverse sections).

POTENTIAL THERAPEUTIC AGENTS IN CHRONIC AND PROGRESSIVE TENDINOPATHY

This paper has explored pathological mechanisms that are implicated in tendinopathy. By understanding better the pathology responsible for chronic progressive tendinopathy, this gives us the potential to rationally assess therapies that may be of benefit.

Chronic tendinopathy should be regarded as a process of degradation which appears to involve many aspects of the chronic injury–repair response, in common with other musculoskeletal rheumatological disorders. This degradation process, with characteristic features of neovessel formation, neoinnervation and synovitis, provides us with potential targets to modify the degradation process in a positive way.

This section of the paper describes the potential for ‘anti-inflammatory’ and other strategies to beneficially modulate both the chronic tendinopathy degradation and progressive tendinopathy process.

Anti-inflammatory strategies and chronic tendinopathy

Over the last 15 years the use of NSAIDs and corticosteroids has become less fashionable and more controversial in the management of chronic tendinopathy. But what does the evidence tell us? If inflammatory mediators are part of ongoing tendinopathy we should expect anti-inflammatory strategies to be at least partially effective in reducing tendon pain.

Corticosteroids

There is substantial evidence that corticosteroids can be effective in chronic tendinopathy at relieving pain, reducing swelling and improving function in the short term—although at the expense of greater risk of long-term recurrence.

This evidence extends to tendinopathy in many locations including patellar tendinopathy^{17 49 50} and lateral epicondylitis.^{51 52} Using an US-guided approach, Fredberg *et al*⁴⁹ demonstrated benefit at 4 weeks, but the non-imaging approach adopted by DaCruz *et al*⁵³ failed to show a benefit. A retrospective study of fluoroscopically guided corticosteroid injection (into the potential space between the paratenon and tendon body) found the procedure to be safe and improvements were seen in 40% at follow-up of 37 months.⁵⁴

A Cochrane review of corticosteroid injection use in shoulder pain has concluded that there is a benefit from subacromial corticosteroid injection in rotator cuff disease over placebo although again the evidence generally extends only to the short term.⁵⁵

The issues relating to corticosteroid injection are therefore less than they do not work, but more that the benefits are generally short term, and that there is the potential for weakening the structural integrity of tendons in the long-term.^{56 57}

The exact mechanism by which corticosteroids have an effect on tendon pain is unclear. Corticosteroids are to some extent indirect vasoconstrictors, through suppression of production of the vasodilators prostacyclin and nitric oxide (NO) as well as exhibiting anti-inflammatory effects. They may also influence the perception of pain by altering local nociception.

The challenge is to determine exactly how corticosteroids exert their beneficial effect on nociceptive and inflammatory pathways, and to develop more refined future therapies without the long-term increased risk of symptom recurrence.

Non-steroidal anti-inflammatory drugs

NSAIDs have a more specific anti-inflammatory role when compared with that of corticosteroids and remain in common clinical use. Most are non-selective inhibitors of COX which

catalyses the formation of prostaglandins and thromboxane from arachidonic acid.

In a review of NSAIDs in tendinopathy, Almekinders and Temple⁵⁸ found pain relief in five of nine prospective and placebo-controlled studies. A more recent review of NSAIDs including 17 placebo-controlled studies confirmed NSAIDs were effective in relieving pain in the short term (7–14 days) in 14 of the 17 studies.⁵⁹ A Cochrane review of interventions for treating acute and chronic Achilles tendinitis found weak evidence of a moderate effect of NSAIDs, both oral and topical, on acute tendon pain.⁶⁰

The beneficial effects of NSAIDs on tendon pain may be related to their anti-inflammatory properties or possibly via analgesia effect/modulation of nociception.² Unlike acetaminophen (paracetamol), which is not considered an NSAID and whose nociceptive effects are mainly mediated by blocking COX activity in the central nervous system (CNS), most NSAIDs penetrate poorly into the CNS, and indeed topical NSAIDs would not be expected to reach levels within the CNS capable of exerting a clinically meaningful analgesic effect.

Concerns remain in relation to the use of NSAIDs both in terms of systemic effects⁶¹ and the potential to affect tendon healing. In relation to tendon healing, in animal studies conflicting results have been noted with either an increase in tensile strength or a reduction in breaking point being reported.²

The key point here is that the apparent effect of NSAIDs on tendon pain in multiple studies suggests a potential role of inflammation in chronic tendinopathy.

Antitumor necrosis factor α agents

Tumour necrosis factor α (TNF- α) is a pro-inflammatory cytokine that is capable of inducing a profound inflammatory response by upregulating pro-inflammatory agents including IL-1, IL6, MMP1 and MMP3, VEGF and PGE₂.⁶² Upregulation of TNF- α is associated with apoptosis; apoptosis being a feature of chronic tendinopathy.⁶³

Inhibition of TNF- α , by synthetic monoclonal biological agents (either as a neutralising antibody or a soluble TNF receptor) is highly effective in treating inflammation associated with active RA and sero-negative spondyloarthritis including ankylosing spondylitis. These agents have powerful anti-inflammatory actions and have been shown to regulate IL6, IL8, MCP-1 and VEGF, reduce angiogenesis and reduce blood levels of MMP-1 and MMP-3.⁶² These monoclonal antibodies are potent inhibitors of TNF.

The use of weakly (less potent) anti-TNF agents in acute tendinopathy has been advocated by others.⁶⁴ Just one study to date has examined the use of the potent anti-TNF- α in chronic tendinopathy. Peritendinous use of adalimumab (a fully humanised anti-TNF receptor antagonist) has been used in chronic Achilles tendinopathy. In this small study, it was found that adalimumab injections had a significant effect on pain sensitisation at rest in chronic Achilles tendinopathy and reduced blood flow at 12 weeks.⁵⁰

Use of these agents in a systemic manner is not straightforward and has not yet been studied. They are expensive (approximately £10 000 per inflammatory arthritis patient treated per calendar year). Additionally, they are powerful immunosuppressants with re-activation of latent TB a particular and serious concern.

Nevertheless, the pilot study demonstrates that targeting TNF- α or other inflammatory cytokines could be a valid approach in chronic progressive tendinopathy. More studies are required.

Matrix metalloproteinase activity, inhibition and regulation

The extra cellular matrix (ECM) in the main body of the tendon consists primarily of type I collagen, while the predominant proteoglycan component is the small leucine-rich proteoglycan decorin, and the principal large aggregating proteoglycan is versican.⁶⁵

Proteoglycan processing is a normal part of tendon physiology. Over their lifespan tenocytes are active and involved in both the production of tendon matrix proteins (including MMPs) and matrix degrading enzymes (tissue inhibitors of metalloproteinases or TIMPs).^{44 45} Both MMPs (through their broad proteolytic capability) and TIMPs are involved in the physiological remodelling of the ECM.^{46 66}

Thus in health the matrix is in a constant state of flux between synthesis and degradation and regulated by this activity of MMPs and TIMPs. However imbalances of MMPs or TIMPs may produce collagen disturbances in tendons.⁶⁷ Jones *et al* have demonstrated reduced expression of ADAMTS-5 levels in tendinopathy and, via mRNA profiling of genes from MMP, ADAMTS and TIMP families, that normal, chronically painful and ruptured tendons have distinct proteolytic mRNA profiles.⁶⁶

This is further evidence to support the view that chronic tendinopathy is not just a passive process but is an active process of degradation. This raises the possibility that manipulation of MMP pathways could beneficially alter pain and/or tendon matrix degradation. The metalloproteinase ADAMTS-5, for example, is already considered a potential target for the treatment of osteoarthritis and attempts are being made to identify small molecules which may inhibit this enzyme.⁶⁸

Substance P, glutamate and pain inhibition as a potential therapy in tendinopathy

Substance P has long been recognised as an important molecule in nociception and pain signalling. Substance P has been found in increased levels in chronic tendon pathology.³⁴ It is increased following overload of the rabbit Achilles tendon⁶⁹ and also accelerates hypercellularity and angiogenesis.⁴³

Increased levels of glutamate, originally thought to be confined to the CNS have been documented to be present in microdialysis of symptomatic Achilles tendon tissue.⁷⁰ Furthermore, elevated levels of the glutamate receptor, N-methyl-D-aspartate receptor type 1 (NMDAR1) have also been documented in chronic tendinopathy.⁷¹ In this study of patients with symptomatic patellar tendinopathy there was a 9-fold increase of NMDAR1 and a 10-fold increase of glutamate compared with controls.

It was suggested by the authors of this paper that the neuronal coexistence of elevated NMDAR1 and glutamate suggests a regulatory role in intensified pain signalling. Coexistence is the presence of two or more transmitters in a single neuron.⁷² This leads to the possibility that inhibition of substance P and/or glutamate could be beneficial not only in reducing pain but also in reducing ongoing tendon degradation.

Neovessels: can we inhibit their formation?

If the process of neovascularisation leads to painful neoinnervation then treatments that stop or hinder the neovascularisation may be successful at reducing the pain in chronic tendinopathy. Current treatments (eg, high-volume injections) treat neovessels once they have occurred, but there is a tendency for the neovessels to reform postprocedure. Potentially, agents that inhibit VEGF and other agents involved in neovessel formation may inhibit their formation and propagation.

Nerve growth factor (NGF) is essential for the maintenance of both sensory and sympathetic neurones and refers to a single

protein. Nerve growth factor belongs to a family of factors also known as neurotrophins and include brain-derived neurotrophic factor (BDNF). Both NGF and BDNF together with the neurotrophin receptor p75 have been detected in Achilles tendon tenocytes.⁷³ NGF is believed to play a role in the development of neuropathic pain. NGF inhibitors, including the monoclonal antibody to NGF tanezumab, are currently undergoing phase 2 clinical trials and, if the trials are successful, could be an option in chronic tendon pain with neoinnervation.

CONCLUSION

Tendinopathy remains both an extremely common condition and a condition with few truly effective treatments.

Over the last decade various models have been proposed to explain the pathological process underpinning tendinopathy. These models have suggested a primarily degenerative pathological process and some have clearly stated that the process of tendon overuse pathology is non-inflammatory in nature. Indeed this has become a paradigm for thinking about tendinopathy.

This paper has highlighted the limitations of this current view. More modern research tools have confirmed the presence of inflammatory cells including macrophages and lymphocytes in chronic tendinopathy, particularly in closely associated tissue (eg, bursa or paratenon). In addition to inflammatory cells, there is evidence that numerous other mediators including substance P, MMPs, VEGF and COX which play a role in chronic tendon pathology.

This does not mean that the pathology of chronic tendinopathy mirrors that of inflammatory arthritis. We do not advocate going back to the 'tendinitis' model, and there is no doubt that a shift away from primarily anti-inflammatory strategies has had great benefit for tendinopathy treatments, by placing the emphasis on active rehabilitation to attempt to regain function and potentially lead to enhanced tissue remodelling.

Mechanical overload is still likely to be the dominant factor involved in initiation of an inflammatory response—the point is that at least some of the damage caused by this overload is mediated through a process that involves elements of the inflammatory process.

An appreciation of the basic science involved in tendinopathy gives us a whole new potential armamentarium of treatments that we can use. It is hoped that tendon research will be driven by a greater awareness of the potential for managing and targeting the inflammatory response.

What this paper add to this subject?

- ▶ Chronic tendinopathy incorporates elements of the inflammatory response.
- ▶ The term tendinosis should not be used to describe the radiological appearances of neovascularisation.
- ▶ More emphasis should be placed on the potential for anti-inflammatory strategies in chronic tendinopathy.

Competing interests None.

Contributors JR and MS have contributed to the original concept, research, writing of article, editing and approval of the final draft. AS has given suggestions on original concept, editing, additional ideas and approval of the final draft.

Provenance and peer review Not commissioned; externally peer reviewed.

Open Access This is an Open Access article distributed in accordance with the Creative Commons Attribution Non Commercial (CC BY-NC 3.0) license, which permits others to distribute, remix, adapt, build upon this work non-commercially, and license their derivative works on different terms, provided the original work is properly cited and the use is non-commercial. See: <http://creativecommons.org/licenses/by-nc/3.0/>

REFERENCES

- Khan KM, Cook JL, Maffulli N, *et al.* Time to abandon the "tendinitis" myth. *BMJ* 2002;16:626–7.
- Rees JD, Wilson AM, Wolman RL. Current concepts in the management of tendon disorders. *Rheumatology* 2006;45:508–21.
- Rees JD, Maffulli N, Cook J. Management of tendinopathy. *Am J Sports Med* 2009;37:1855–67.
- Puddu G, Ippolito E, Postacchini F. A classification of Achilles tendon disease. *Am J Sports Med* 1976;4:145–50.
- Aström M, Rausing A. Chronic Achilles tendinopathy. A survey of surgical and histopathologic findings. *Clin Orthop Relat Res* 1995;316:151–64.
- Józsa L, Kannus P. Histopathological findings in spontaneous tendon ruptures. *Scand J Med Sci Sports* 1997;2:113–18.
- Khan KM, Cook JL, Bonar F, *et al.* Histopathology of common tendinopathies. Update and implications for clinical management. *Sports Med* 1999;27:393–408.
- Zamora AJ, Marini JF. Tendon and myo-tendinous junction in an overloaded skeletal muscle of the rat. *Anat Embryol (Berl)* 1988;179:89–96.
- Clancy W. Failed healing responses. In: Leadbetter W, Buckwater J, Gordon S, eds. *Tendon trauma and overuse injuries*. Park Ridge, IL: American Orthopedic Society for Sports Medicine, 1989, 609–18.
- Cook JL, Puram CR. Is tendon pathology a continuum? A pathology model to explain the clinical presentation of load-induced tendinopathy. *Br J Sports Med* 2009;43:409–16.
- Alfredson H, Pietila T, Jonsson P, *et al.* Heavy-load eccentric calf muscle training for the treatment of chronic Achilles tendinosis. *Am J Sports Med* 1998;26:360–6.
- Rompe JD, Nafe B, Furia JP, *et al.* Eccentric loading, shock-wave treatment, or a wait-and-see policy for tendinopathy of the main body of tendo Achilles: a randomized controlled trial. *Am J Sports Med* 2007;35:374–83.
- Larsson ME, Käll I, Nilsson-Helander K. Treatment of patellar tendinopathy—a systematic review of randomized controlled trials. *Knee Surg Sports Traumatol Arthrosc* 2012;20:1632–46.
- Cardoso de Souza M, Trajano Jorge R, Jones A, *et al.* Progressive resistance training in patients with shoulder impingement syndrome: literature review. *Reumatismo* 2009;61:84–9.
- Raman J, MacDermid JC, Grewal R. Effectiveness of different methods of resistance exercises in lateral epicondylitis—a systematic review. *J Hand Ther* 2011;25:5–25.
- Silbernagel KG, Thomeé R, Thomeé P, *et al.* Eccentric overload training for patients with chronic Achilles tendon pain—a randomised controlled study with reliability testing of the evaluation methods. *Scand J Med Sci Sports* 2001;11:197–206.
- Kongsgaard M, Kovanen V, Aagaard P, *et al.* Corticosteroid injections, eccentric decline squat training and heavy slow resistance training in patellar tendinopathy. *Scand J Med Sci Sports* 2009;19:790–802.
- Smith RK. Mesenchymal stem cell therapy for equine tendinopathy. *Disabil Rehabil* 2008;30:1752–8.
- Kaux JF, Forthomme B, Le Goff C, *et al.* Current opinions on tendinopathy. *J Sport Sci Med* 2011;10:238–53.
- Suresh SPS, Ali KE, Jones H, *et al.* Is ultrasound guided autologous blood injection an effective treatment? *Br J Sports Med* 2006;40:935–39.
- Connell DA, Ali KE, Ahmad M, *et al.* Ultrasound-guided autologous blood injection for tennis elbow. *Skeletal Radiol* 2006;35:371–7.
- De Vos RJ, Weir A, van Schie HTM, *et al.* Platelet-rich plasma injection for chronic Achilles tendinopathy. *JAMA* 2010;303:144–9.
- Alfredson H, Ohberg L, Forsgren S. Is vasculo-neural ingrowth the cause of pain in chronic Achilles tendinosis? An investigation using ultrasonography and colour Doppler, immunohistochemistry, and diagnostic injections. *Knee Surg Sports Traumatol Arthrosc* 2003;11:334–8.
- Alfredson H, Ohberg L. Sclerosing injections to areas of neo-vascularisation reduce pain in chronic Achilles tendinopathy: a double-blind randomised controlled trial. *Knee Surg Sports Traumatol Arthrosc* 2005;13:338–44.
- Chan O, O'Dowd D, Padhiar N, *et al.* High volume image guided injections in chronic Achilles tendinopathy. *Disabil Rehabil* 2008;30:1697–708.
- Maffulli N, Longo UG, Denaro V. Novel approaches for the management of tendinopathy. *J Bone Joint Surg Am* 2010;92:2604–13.
- Schubert TE, Weidler C, Lerch K, *et al.* Achilles tendinosis is associated with sprouting of substance P positive nerve fibres. *Ann Rheum Dis* 2005;64:1083–6.
- Gotoh M, Hamada K, Yamakawa H, *et al.* Significance of granulation tissue in torn supraspinatus insertions: an immunohistochemical study with antibodies against interleukin-1 beta, cathepsin D, and matrix metalloproteinase-1. *J Orthop Res* 1997;15:33–9.
- Sullo A, Maffulli N, Capasso G, *et al.* The effects of prolonged peritendinous administration of PGE1 to the rat Achilles tendon: a possible animal model of chronic Achilles tendinopathy. *J Orthopaed Sci* 2001;6:349–57.
- Zhang J, James H-C. Wang production of PGE2 increases in tendons subjected to repetitive mechanical loading and induces differentiation of tendon stem cells into non-tenocytes. *J Orthop Res* 2010;28:198–203.
- Khan MH, Li Z, Wang JH. Repeated exposure of tendon to prostaglandin-E2 leads to localized tendon degeneration. *Clin J Sport Med* 2005;15:27–33.
- Legerlotz K, Jones ER, Screen HR, *et al.* Increased expression of IL-6 family members in tendon pathology. *Rheumatology (Oxford)* 2012;51:1161–5.
- Fenwick SA, Hazleman BL, Harrall RL, *et al.* Transforming growth factor- β isoform expression in chronic Achilles tendinopathy and their effects on tendon cell populations. *Int J Exp Pathol* 2000;81:A11–12.
- Gotoh M, Hamada K, Yamakawa H, *et al.* Increased substance P in subacromial bursa and shoulder pain in rotator cuff diseases. *J Orthop Res* 1998;16:618–21.
- Backman C, Boquist L, Fridén J, *et al.* Chronic Achilles paratenonitis with tendinosis: an experimental model in the rabbit. *J Orthop Res* 1990;8:541–7.
- Scott A, Cook JL, Hart DA, *et al.* Tenocyte responses to mechanical loading in vivo: a role for local insulin-like growth factor 1 signaling in early tendinosis in rats. *Arthritis Rheum* 2007;56:871–81.
- Nakamura H, Yoshino S, Kato T, *et al.* T-cell mediated inflammatory pathway in osteoarthritis. *Osteoarthritis Cartilage*, 1999;7:401–2.
- Shen PC, Wu CL, Jou IM, *et al.* T helper cells promote disease progression of osteoarthritis by inducing macrophage inflammatory protein-1 γ . *Osteoarthritis Cartilage* 2011;19:728–36.
- Huss RS, Huddleston JI, Goodman SB, *et al.* Synovial tissue-infiltrating natural killer cells in osteoarthritis and periprosthetic inflammation. *Arthritis Rheum* 2010;62:3799–805.
- Rees JD, Pilcher J, Heron C, *et al.* A comparison of clinical vs ultrasound determined synovitis in rheumatoid arthritis utilizing gray-scale, power Doppler and the intravenous microbubble contrast agent 'Sono-Vue'. *Rheumatology (Oxford)* 2007;46:454–9.
- Carmeliet P. Angiogenesis in health and disease. *Nat Med* 2003;9:653–60.
- Taylor PC, Steuer A, Cosgrove DO, *et al.* Comparison of ultrasonographic assessment of synovitis and joint vascularity with radiographic evaluation in a randomized, placebo-controlled study of infliximab therapy in early rheumatoid arthritis. *Arthritis Rheum* 2004;50:1107–16.
- Andersson G, Backman LJ, Scott A, *et al.* Substance P accelerates hypercellularity and angiogenesis in tendon tissue and enhances paratenonitis in response to Achilles tendon overuse in a tendinopathy model. *Br J Sports Med* 2011;45:1017–22.
- Riley GP, Curry V, DeGroot J, *et al.* Matrix metalloproteinase activities and their relationship with collagen remodelling in tendon pathology. *Matrix Biol* 2002;21:185–95.
- Riley G. The pathogenesis of tendinopathy. A molecular perspective. *Rheumatology* 2004;43:131–42.
- Magra M, Maffulli N. -Matrix metalloproteinases: a role in overuse tendinopathies. *Br J Sports Med* 2005;39:789–91.
- Fong G, Backman LJ, Hart DA, *et al.* Substance P enhances collagen remodeling and MMP-3 expression by human tenocytes. *J Orthop Res* 2013;31:91–8.
- Garrett NE, Mapp PI, Cruwys SC, *et al.* Role of substance P in inflammatory arthritis. *Ann Rheum Dis* 1992;51:1014–18.
- Capasso G, Testa V, Maffulli N, *et al.* Aprotinin, corticosteroids and normosaline in the management of patellar tendinopathy in athletes; a prospective randomized study. *Sports Exerc Inj* 1997;3:111–15.
- Fredberg U, Ostgaard R. Effect of ultrasound-guided, peritendinous injections of adalimumab and anikininra in chronic Achilles tendinopathy. *Scand J Med Sci Sports* 2009;19:338–44.
- Nimgade A, Sullivan M, Goldman R. Physiotherapy, steroid injections, or rest for lateral epicondylitis? What the evidence suggests. *Pain Pract* 2005;5:203–15.
- Bisset L, Beller E, Jull G, *et al.* Mobilisation with movement and exercise, corticosteroid injection, or wait and see for tennis elbow: randomised trial. *BMJ* 2006;333:939.
- DaCruz DJ, Geeson M, Allen MJ, *et al.* Achilles paratenonitis: an evaluation of steroid injection. *Br J Sports Med* 1988;22:64–5.
- Gill SS, Gelbke MK, Mattson SL, *et al.* Fluoroscopically guided low-volume peritendinous corticosteroid injection for Achilles tendinopathy. A safety study. *J Bone Joint Surg Am* 2004;86:802–6.
- Buchbinder R, Green S, Youd JM. Corticosteroid injections for shoulder pain. *Cochrane Database Syst Rev* 2003;(1):CD004016.
- Kleinman M, Gross AE. Achilles tendon rupture following steroid injection: report of three cases. *J Bone Joint Surg Am* 1983;65:1345–7.
- Ford LT, DeBender J. Tendon rupture after local steroid injection. *South Med J* 1979;72:827–30.
- Almekinders LC, Temple JD. Etiology, diagnosis, and treatment of tendonitis: an analysis of the literature. *Med Sci Sports Exerc* 1998;30:1183–90.
- Andres BM, Murrell GA. Treatment of tendinopathy: What works, what does not, and what is on the horizon. *Clin Orthop Relat Res* 2008;466:1539–54.

- 60 McLauchlan G, Handoll HHG. Interventions for treating acute and chronic Achilles tendinitis. Editorial Group: *Cochrane Bone, Joint and Muscle Trauma Group*. Published Online: 21 Jan 2009 Assessed as up-to-date: 29 Dec 2000.
- 61 Lanas A, Perez-Aisa MA, Feu F, et al. A nationwide study of mortality associated with hospital admission due to severe gastrointestinal events and those associated with nonsteroidal antiinflammatory drug use. *Am J Gastroenterol* 2005;100:1685–93.
- 62 Feldmann M, Maini RN. Anti-TNF alpha therapy of rheumatoid arthritis: what have we learned? *Ann Rev Immunol* 2001;19:163–96.
- 63 Rath CC, Aggarwal BB. TNF-induced signalling in apoptosis. *J Clin Immunol* 1999;19:350–64.
- 64 Fallon K, Purdam C, Cook J, et al. A "polypill" for acute tendon pain in athletes with tendinopathy?. *J Sci Med Sport* 2008;11:235–8.
- 65 Corps AN, Robinson AH, Movin T, et al. Versican splice variant messenger RNA expression in normal human Achilles tendon and tendinopathies. *Rheumatology (Oxford)* 2004;43:969–72.
- 66 Jones GC, Corps AN, Pennington CJ, et al. Expression profiling of metalloproteinases and tissue inhibitors of metalloproteinases in normal and degenerate human Achilles tendon. *Arthritis Rheum* 2006;54:832–42.
- 67 Karousou E, Ronga M, Vigetti D, et al. Collagens, proteoglycans, MMP-2, MMP-9 and TIMPs in human Achilles tendon rupture. *Clin Orthop Relat Res* 2008;466:1577–82.
- 68 Deng H, O'Keefe H, Davie CP, et al. Discovery of highly potent and selective small molecule ADAMTS-5 inhibitors that inhibit human cartilage degradation via encoded library technology (ELT). *J Med Chem* 2012;55:7061–79.
- 69 Backman LJ, Andersson G, Wennstig G, et al. Endogenous substance P production in the Achilles tendon increases with loading in an in vivo model of tendinopathy-peptidergic elevation preceding tendinosis-like tissue changes. *J Musculoskelet Neuronal Interact* 2011;11:133–40.
- 70 Alfredson H, Thorsen K, Lorentzon R. In situ microdialysis in tendon tissue: high levels of glutamate, but not prostaglandin E2 in chronic Achilles tendon pain. *Knee Surg Sports Traumatol Arthrosc* 1999;7:378–81.
- 71 Carlsson NS, Li J, et al. Substance P injections enhance tissue proliferation and regulate sensory nerve ingrowth in rat tendon repair. *Scand J Med Sci Sports* 2011;4:562–9.
- 72 Merighi A. Neuropeptides and coexistence. In: *Intercellular communication in the nervous system ed robert malenka*, London: Academic Press, Elsevier, 2009:525–9.
- 73 Bagge J, Lorentzon R, Alfredson H, et al. Unexpected presence of the neurotrophins NGF and BDNF and the neurotrophin receptor p75 in the tendon cells of the human Achilles tendon. *Histol Histopathol* 2009;24:839–48.

1. The following terms best describe tendinosis.

- A painful tendon
- A tendon which demonstrates grey scale changes on ultrasound (US) (such as thickening and hypoechogenicity).
- It is a histological term reserved for the histological appearance of a tendon.
- Can be correctly diagnosed on MRI scan.
- Implies inflammation is present.

Correct answer—C. The term tendinosis, although used regularly to describe the US and MRI appearances of a tendon, is actually defined as a tendon demonstrating degenerative change and devoid of an inflammatory infiltrate. Therefore this term should not be used to describe the appearances of a tendon using a US or an MRI.

2. Inflammation is most appropriately described by;

- A "multi-mediated phenomenon, of a pattern type in which all mediators would come and go at the appropriate moment... increasing vascular permeability, attracting leucocytes, producing pain, local edema and necrosis".
- Always characterized by the presence of all five cardinal signs: heat, swelling, redness, pain and loss of function.
- Never occurring in tendons or their surrounding tissues (paratendon, bursae etc).
- The focus of treatment for a patient with chronic tendinopathy.
- Always being necessary for tissue healing.

Correct answer: A. The biochemical definition of inflammation (Rocha e Silva, 1974) is widely accepted today. Inflammation is

not a single phenomenon. It is a rather wide-reaching concept, which includes a multitude of events which may occur together or independently to varying extents. Thus, elements of an inflammatory response may be present without all five cardinal signs. Following either acute injuries (eg, laceration and contusion) or acute bouts of mechanical load, both the tendon and its surrounding tissues may experience bouts of inflammation. Over time, this may lead to the loss of tendon structure, scarring, adhesions, metaplasia etc. The focus of treatment for a chronic tendinopathy should be load management and graduated rehabilitation with attention to optimal biomechanics. Tissue healing can occur through intrinsic cellular activity, in the absence of inflammatory cells or cardinal signs.

3. Regarding neo-vascularity, which of the following statements is most appropriate?

- The presence of neo-vessels confirms a diagnosis of tendinosis.
- The extent of neo-vascularity correlates well with the clinical severity of tendinopathy.
- The appearances of a tendon in clinically confirmed ankylosing spondylitis are often indistinguishable from those of a case of 'degenerative' tendinopathy when visualised on power Doppler US.
- Neo-vessels are only seen in tendinopathy.
- Insulin-like growth factor 1 (IGF-1) is thought to be responsible for the formation of both neo-vascularity and neo-innervation.

Answer C. Tendinosis is only a histological diagnosis. Neo-vascularity does not necessarily correlate well with clinical severity. Neo-vessels are seen in a number of other pathologies such as rheumatoid arthritis, ankylosing spondylitis and diabetic retinopathy. Vascular endothelial growth factor (VEGF) is thought responsible for the neo-vessel formation.

4. Regarding denervation techniques performed on tendons:

- They are techniques performed on the tendon directly.
- The main aim is to improve tendon healing.
- The effect is believed to be through the interruption of neural stimulation.
- These techniques are usually performed surgically.
- They are usually performed with blood or blood products.

Correct answer—C. Denervation techniques, such as high-volume paratenon stripping of the Achilles tendon, do not require surgery although surgical variants have been described. The beneficial effect is believed to be through interruption of neural ingrowth and/or nociceptive input. They are not performed with blood or blood products.

5. Which of the following statements regarding substance-P is incorrect?

- It is a neuropeptide.
- Along with calcitonin gene-related peptide (CGRP), it is significantly expressed in chronic tendinopathy.
- It acts as a proinflammatory mediator.
- It increases the ratio of type IV: type I collagen mRNA, which could contribute to the formation of smaller collagen fibres seen in tendinopathic tendons.
- It coexists with the neurotransmitter glutamate in primary afferents that respond to painful stimuli.

Answer D. Increases the ratio of type III: type I collagen. All other statements are correct.



Tendons – time to revisit inflammation

Jonathan D Rees, Matthew Stride and Alex Scott

Br J Sports Med published online March 9, 2013
doi: 10.1136/bjsports-2012-091957

Updated information and services can be found at:
<http://bjsm.bmj.com/content/early/2013/03/08/bjsports-2012-091957.full.html>

These include:

- References** This article cites 69 articles, 17 of which can be accessed free at:
<http://bjsm.bmj.com/content/early/2013/03/08/bjsports-2012-091957.full.html#ref-list-1>
- Open Access** This is an open-access article distributed under the terms of the Creative Commons Attribution Non-commercial License, which permits use, distribution, and reproduction in any medium, provided the original work is properly cited, the use is non commercial and is otherwise in compliance with the license. See:
<http://creativecommons.org/licenses/by-nc/3.0/> and
<http://creativecommons.org/licenses/by-nc/3.0/legalcode>
- P<P** Published online March 9, 2013 in advance of the print journal.
- Email alerting service** Receive free email alerts when new articles cite this article. Sign up in the box at the top right corner of the online article.
-

- Topic Collections** Articles on similar topics can be found in the following collections
- [Open access](#) (121 articles)
 - [Drugs: musculoskeletal and joint diseases](#) (82 articles)
-

Advance online articles have been peer reviewed, accepted for publication, edited and typeset, but have not yet appeared in the paper journal. Advance online articles are citable and establish publication priority; they are indexed by PubMed from initial publication. Citations to Advance online articles must include the digital object identifier (DOIs) and date of initial publication.

To request permissions go to:
<http://group.bmj.com/group/rights-licensing/permissions>

To order reprints go to:
<http://journals.bmj.com/cgi/reprintform>

To subscribe to BMJ go to:
<http://group.bmj.com/subscribe/>

Notes

Advance online articles have been peer reviewed, accepted for publication, edited and typeset, but have not yet appeared in the paper journal. Advance online articles are citable and establish publication priority; they are indexed by PubMed from initial publication. Citations to Advance online articles must include the digital object identifier (DOIs) and date of initial publication.

To request permissions go to:

<http://group.bmj.com/group/rights-licensing/permissions>

To order reprints go to:

<http://journals.bmj.com/cgi/reprintform>

To subscribe to BMJ go to:

<http://group.bmj.com/subscribe/>